

**EVOLUTION OF TWO METHODS OF EXPERIMENTAL APICAL
DESMOTOMY AS SURGICAL ALTERNATIVES IN BOVINES RUFFIAN
PREPARATION**

RABELO, Rogério Elias

DVM, PhD, Professor, Campus Jataí, UFG, Goiás, Brazil. Address: BR364 km 192
Nº 3800, Campus Jatobá – Setor Industrial. CEP: 75801615/ Jataí- GO. Phone:
+556436068326. rabelovet@yahoo.com.br

VULCANI, Valcinir Aloísio Scalla

DVM, PhD, Professor, Campus Jataí, UFG, Goiás, Brazil. Address: BR364 km 192
Nº 3800, Campus Jatobá – Setor Industrial. CEP: 75801615/ Jataí- GO.

SANT'ANA, Fabiano José Ferreira de

DVM, PhD, Professor, Campus Jataí, UFG, Goiás, Brazil. Address: BR364 km 192 Nº
3800, Campus Jatobá – Setor Industrial. CEP: 75801615/ Jataí- GO.

DAMASCENO, Adilson Donizeti

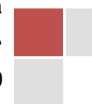DVM, PhD, Professor, Department of Veterinary medicine, Veterinary College,
UFG, Goiás, Brazil.

LIMA, Caroline Rocha de Oliveira

DVM, Msc., Post Graduation Program in Animal Science, Veterinary College, UFG,
Goiás, Brazil

SOUSA, Nicaelle Luan de Moura

Graduate student, UFG, Campus Jatai, Goiás, Brazil.



ABSTRACT

The aim of this study was to compare the total and partial resection of the apical ligament of the penis as alternative surgical procedures for bovine ruffians preparation. Twenty-four 20 months-old male crossbred steers were divided into two groups (GI and GII). In GI, apical ligament was only sectioned, while, in GII 2-centimeter length fragment was removed. Penile deviation was not observed in group GI but observed in GII. In group GII The partial removal of the ligament can be recommended as an alternative method in the preparation of teaser cattle.

Keywords: longitudinal dorsal ligament, ruffian, bull, copule, desmotomy

INTRODUCTION

Success in insemination programs and controlled breeding depends on determination of the exact time to insemination. However, many factors may difficult the estrus detection resulting in damages. Thus, the use of ruffians has a great importance, since they allow the detection of female in estrus besides the induction of estrus and ovulation due to psychosexual excitement.

Several surgical techniques are used for bovine ruffian preparation. Procedures can be classified as those that allow copulation without female fertilization and those in which the copulation does not occur. As examples of the first, bilateral epididymectomy and scarification of the cauda epididymidis are easy procedures but have risk of reproductive disease transmission Eurides e Silva (2002). The methods that prevent exposure of the penis, as the caudal fixation of flexura sigmoidea and penis adherence in abdominal wall are easy and inexpensive, however, in spite of highly recommendation they are associated to the loss of libido Silva et al (2001).

The techniques that induce penile deviation with impairment of coitus, as lateral and ventral prepuce deviation penile deviation through the subcutaneous tunnel and the method of the new preputial ostium are considered efficient and maintain libido,

Revista Científica Eletrônica de Medicina Veterinária é uma publicação semestral da Faculdade de Medicina veterinária e Zootecnia de Garça - FAMED/FAEF e Editora FAEF, mantidas pela Associação Cultural e Educacional de

Garça ACEG. CEP: 17400-000 - Garça/SP - Tel.: (0**14) 3407-8000

www.revista.inf.br - www.editorafaef.com.br - www.faeff.edu.br.

however, are laborious, expensive and require an intensive postoperative care in comparison to other techniques Carneiro (1975), Walker e Vaughan (1980), Eurides e Silva (2002), Silva et al (2002), Nolasco et al (2004).

The apical ligament of the bull penis is constituted of collagen fibers arising from the tunica albuginea that allow maintenance of the distal portion of the penis in erection during the copulation and adjust the physiological spiral deviation for adequate penis introduction into the female genitalia Ashdown e Pearson (1971), Rabelo et al (2008), Cardoso (2010). Based on this, studies have pointed the desmotomy of apical ligament as an alternative method for preparation of bovine ruffian Rabelo et al (2009).

Thus, the aim of this study was to compare the total and partial resection of the apical ligament of the penis as alternative surgical procedures for bovine ruffians preparation, considering the following aspects: efficiency of the methods and postoperative complications.

MATERIAL AND METHODS

The experiment was carried out at the School Farm of the Federal University of Goiás, Campus Jataí, Goiás State, Brazil, between April and July, 2010. Twenty four crossbred (*Bos taurus taurus X Bos taurus indicus*) steers with average weight of 270 kg and mean age of 20 months were used. The animals were randomly allocated into two groups (GI and GII) with twelve animals each. The experimental procedures followed the guidelines of The Brazilian College of Animal Experimentation (COBEA). The project was approved by the Ethics Committee in Research of the Federal University of Goiás on October 6, 2009 (protocol nº 073/2009).

Previously, the sexual behavior of the steers was evaluated through the natural breeding in cows with therapeutically induced estrus Chaves (2002). It was selected steers with good libido that performed at least one breeding. There were no abnormalities in genitalia that could interfere in copulation.

Pre-operative care of both groups consisted of 18 hours fasting, bilaterally locoregional anesthesia of the pudendal and hemorrhoidal nerves with 20 ml of 2% lidocaine applied at the lower sciatic foramen and sedation with a combination of 2%

xylazine (0.05 mg/kg) and 1% acepromazine hydrochloride (0.05 mg/kg), both intravenously Tranquili et al. (2007).

The steers were restrained in right lateral recumbency for manual exposure of the penis using gauze. Thus, the region of the reflection of the internal layer of the prepuce was compressed with a strip of latex for preventive hemostasis (Fig. 1A). The antisepsis of the operative field was performed with polyvinyl pyrrolidone-iodine.

Sequentially, it was performed in GI group a five centimeters long incision in tegument of the dorsal surface of the glans starting two centimeters from the end of the of the glans. After this, the apical ligament was isolated, through the left side, with a Halstead curve hemostatic forceps (Fig. 1B) and transversally sectioned (Fig. 1C).

Finally, the surgical procedure was concluded with the reconstruction of the penile tegument with #0 needled chromic catgut in separate simple suture pattern. In GII, it was performed the same procedure, however, it was removed a two centimeters long fragment of the apical ligament of the penis (Fig. 1D).

The postoperative care of both groups consisted of two intramuscular injection of oxytetracycline (20 mg/kg) in 48 hours interval and intra-preputial daily washing with chlorhexidine solution for five consecutive days.



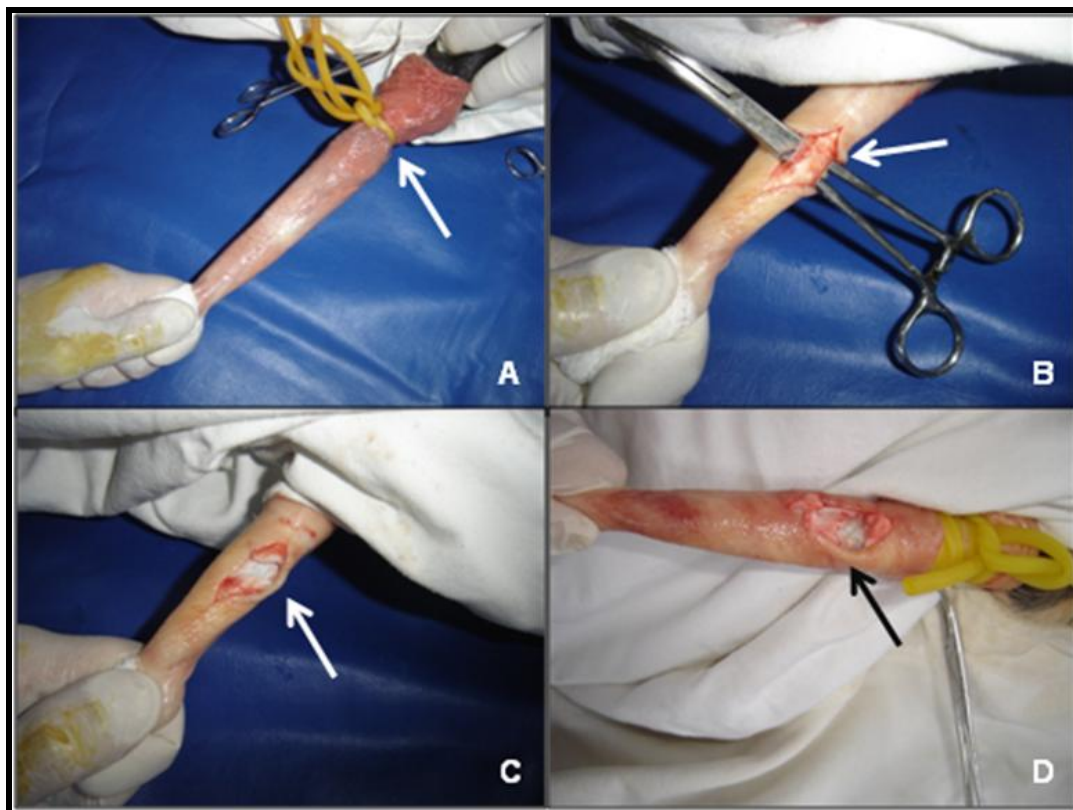


Figure 1 - Surgical procedure to induce penile deviation in bulls. (A) temporary occlusion of the internal layer of the prepuce. (B) Isolation of the apical penile ligament (C) Section of the apical penile ligament in animals of GI (D) Section and removal of a fragment of two centimeters long of the apical penile ligament in animals of GII.

After the 30 days of surgery, the animals of the two groups were submitted to the test of sexual behavior, as previously described, when it was evaluated the presence, degree and type of penile deviation showed by animals and the ability of copulation. For the last, the action was classified as effective, laborious and ineffective.

For effective, it was considered the capability to execute a complete breeding at least. In laborious copula, the bulls carried out a complete breeding, but showed difficulty of inserting the penis into the female genitalia because of penile deviation. Ineffective action was considered when the animals were unable to perform a complete breeding.

For penile deviation, it was considered scores ranging from mild, moderate and intense on dependence of the angle between the normal direction of the penis and the axis of deviation (deviation angle). The deviation angle ranged from five to 20 degrees was considered mild, 20 to 40 degrees was moderate and intense above 40 degrees (Figures 2 A, B, C and D).

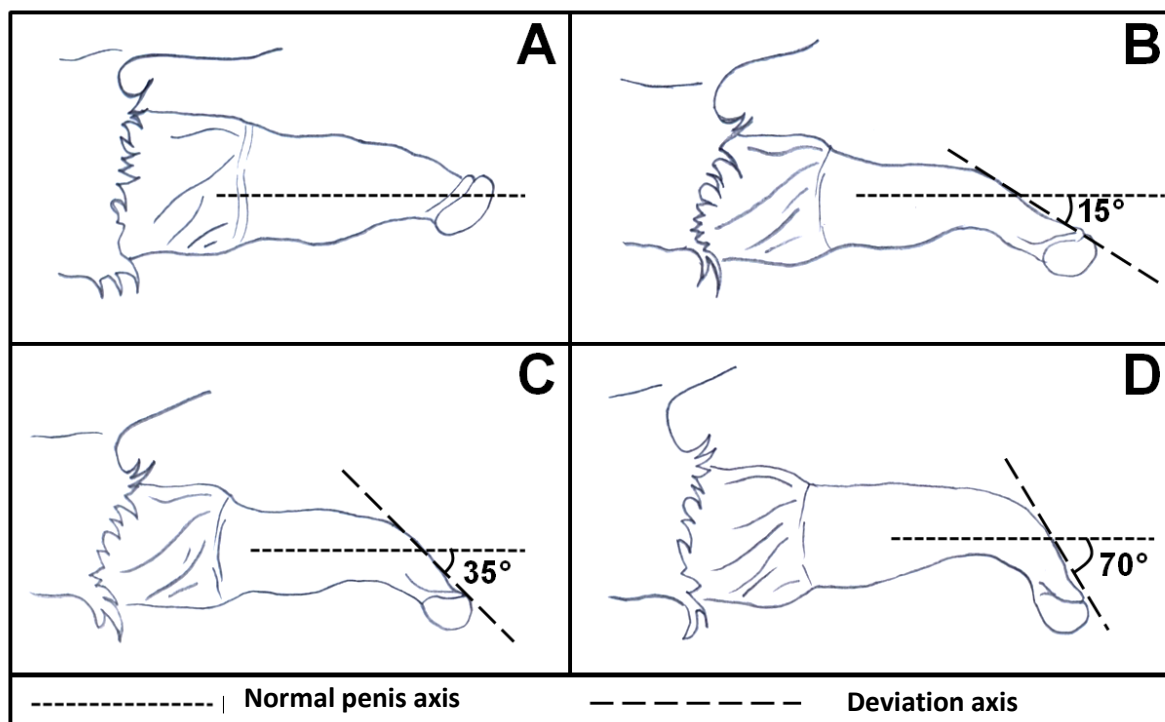


Figure 2 – Representation of different degrees of ventral penile deviation. (A) normal direction, (B) mild deviation, (C) moderate deviation, (D) intense deviation.

The data were statistically analyzed by descriptive analysis for the type and degree of deviation between groups and nonparametric analysis employing the Chi-square for number of animals by type and degree of deviation in the groups. Fisher exact test for analysis of the number of animals of GII by type of deviation and breeding ability were used considering the significance level of 5% Filho (2004).

RESULTS AND DISCUSSION

The anesthetic protocol allowed adequate exposure and maintenance of penis for surgical procedures without painful reaction. Penis exposure may be partially attributed to the action of acepromazine as considered by MASSONE (2003). In respect to anesthesia of the pudendal and hemorrhoidal nerves, the way was considered by MASSONE (2003), SILVA et al. (2004), ASHDOWN (2006) and GARNERO & TURKEYS (2006) as effective in penile exposure and analgesia as observed in this study, allowing the execution of many types of surgical procedures.

Apical ligament of the penis was easily distinguished and isolated from the tunica albuginea with the Halsted curve hemostat forceps as mentioned previously by Ashdown e Smith (1969), Montes et al (1980), Nomina Anatomica Veterinaria (1983), Eurides et al (2006), Bento (2005), Ashdown (2006), Rabelo et al (2008), Rabelo et al (2009). However, in a similar study in sheep and goats, the identification and isolation of the apical ligament of the penis were laborious due to the presence of two distinct apical ligaments and their lateral placement differently of the dorsal position in the bulls Rumph e Garret (1992). Besides, in sheep and goats these ligaments are composed mainly by collagen fibers and elastic fibers.

Two animals of GI (16.66%) and one of GII (8.33%) showed swelling and partial prolapse of the inner preputial sheath 24 hours after the surgery, that were treated with local shower with cold water for ten minutes, once a day, along to the three consecutive days, and only one intramuscular injection of flunixin meglumine (1.1 mg/kg). Probably, the cause of exposure of the penis and the internal preputial sheath was triggered by anesthetic blockade of pudendal and hemorrhoidal nerves and use of acepromazine associated with prolonged lateral recumbency of the animals. It was noted discreet granulation tissue at incision in two (16.66%) bulls of GI and five (41.66%) of GII that was observed just in the first twelve days after the surgery procedure. The other postoperative complications were mild redness and sensitivity.

The test of sexual behavior carried out 30 days after surgery showed that penile deviation was not observed in bulls of GI (Table 1) and copulation was successful performed by all animals. However, in other study, ventral and lateral deviation with breeding incapibility was observed after 25 days of the transversal section of apical

ligament of the penis in all bulls. Probably, the absence of penile deviation in GI is related to the reconstitution of the apical ligament. For Clark (1993) e Raiser (1995), the process of healing and reconstruction of structures such as ligaments and tendons occurs after the collagen production and remodeling (fibroplasia), especially when there is proximity between the proximal and distal fragments. Fibroplasia persists for up to twenty weeks and could explain the results of GI.

Table 1 – Number of animals of groups I and II allocated by type and deviation penile grade in experimentation carried out at the School Farm of the Federal University of Goiás, Campus Jataí, Goiás State, Brazil, April and July, 2010.

Parameteres	Group I		Group II	
	N	%	N	%
Type of deviation				
Absent	12	100,0	–	0,0
Right lateral	–	0,0	8	66,7
Ventral	–	0,0	4	33,3
Total	12	100,0	12	100,00
Grade Deviation				
Absent	-	-	-	0,0
Mild	-	-	4	33,3
Moderate	-	-	5	41,7
Severe	-	-	3	25,0
Total	-	-	12	100,0

P < 0,001 (Chi-Square Test)

In GII, it was observed four (33.33%) bulls with intense lateral deviation, two (16.66%) moderate lateral deviation, five (41.66%) severe ventral deviation and one (8.33%) moderate ventral deviation (Table 2). The steers with moderate to intense penile deviation did not perform breeding effectively during the capacity test facility

(Figure 3). However, there were significant differences for the type and degree of deviation and for the copulation ability ($P > 0,05$). Similar results were described in other studies who described that there are stretch, laceration or degeneration of the fibers of the apical ligament of the bull penis Milne (1954) e Walker (1980). Usually, it is verified ventral or lateral deviation in different degrees and some animals may show inability for copulation.

Table 2 - Number of animals distributed by penile deviation type and copulative capacity in group II in experimentation accomplished carried out at the School Farm of the Federal University of Goiás, Campus Jataí, Goiás State, Brazil, April and July, 2010.

Copulative capacity	Right lateral		Ventral	
	N	%	N	%
Laborious	4	50	-	0,0
Ineffective	4	50	4	100,0
Total	8	100,0	4	100,0

$P = 0,208$ (Fisher Exact Test)




Figure 3 – Bovine ruffian prepared by technique of partial removal of the apical ligament of the penis showed intense deviation and inability of breeding

Findings of this investigation agree partially with previous study of Bento (2005), who described the occurrence of different deviations after removing of a segment of the apical ligament, however, the authors did not specify the size of the portion removed and the degree of penile deviation. As observed in the present study, during the test service capacity, the inability of copula was observed in all animals.

CONCLUSIONS

Under conditions of this experiment, it can be concluded that cutted apical ligament of bull penis allows the maintenance of breeding ability, then the animals must be rejected for use as ruffian. The partial removal of the ligament can be recommended as an alternative method in the preparation of bovine ruffian. Besides, the procedure was efficient, easy, low cost and postoperative complications were few.

REFERENCES

Ashdown, RR, 2006, Functional, developmental and clinical anatomy of the bovine penis and prepuce. *CAB Reviews: Perspectives in agriculture, Veterinary Science, Nutrition and Natural Resources*, Londres 1

Ashdown, RR, Pearson, H, 1971, The functional significance of the dorsal apical ligament of the bovine penis. *Research in Veterinary Science* 12:183

Bento, RT, 2005, *Implante de tendão autólogo do músculo flexor superficial dos dedos no reparo de desvio do pênis de bovinos*. Dissertação (Mestrado em Ciências

Veterinárias). Escola de Veterinária, Universidade Federal de Uberlândia, Uberlândia

Cardoso, JR, Eurides, D, Moreira, PC, et al, 2010, Morfologia e biometria do ligamento apical do pênis de touros da raça Girolando. *Ciência Rural*, 40



Carneiro, MI, 1975, Preparação de rufiões bovinos. Técnicas cirúrgicas para formação de novo óstio prepucial. *Colégio Brasileiro. Reprodução Animal* 1:2-24

Chaves, SM, 2002, *Avaliação de rufiões bovinos preparados pelos métodos do desvio lateral modificado e da aderência do pênis à parede abdominal*. Goiânia, 2002. 116p.

Dissertação (Mestrado). Escola de Veterinária, Universidade Federal de Goiás, Goiânia

Clark, MD, 1993, Tendon injury and repair. In. BOJRAB, M. J. *Disease mechanisms in small animal surgery*, 2.ed. Philadelphia, Lea & Febiger, p.1079

Eurides, D & Silva, LAF, 2002, *Métodos de preparo de rufiões bovinos e equinos*. Goiânia: Editora Talento, 112

Filho, GM, 2004, Segredos da estatística em pesquisa científica. Goiânia: Gráfica e Editora Vieira, 184

Eurides, D, Bento, LRT, Silva, AF, et al, 2006, Implante autólogo de tendão flexor superficial no reparo de desvio de pênis de bovino. In: Implante autólogo de tendão flexor no reparo de desvio de pênis de bovinos, Santos, SP. *Arquivo Brasileiro de Medicina Veterinária e Zootecnia*. Belo Horizonte : FEP MVZ 58:179-179.

Garnero, OJ, Perusia,OR, 2006, *Manual de anestesia e cirurgia de bovinos*. São Paulo: Tecmedd

Massone, F, *Anestesiologia veterinária, 2003*, In: Farmacologia e técnicas. 4 ed. Rio de Janeiro: Guanabara Koogan, p. 326

Milne, FJ, 1954, Penile and prepucial problem in the bull. *Journal of the American Veterinary Medical Association* 124:6-11



Montes, GS, Afonso, CR, Luque, EH, et al, 1980 Anatomia funcional del pene bovino. *Gac. Vet. Bs. As.*, 42:351-373

Nolasco RM, Eurides D, Barbosa CP, et al, 2004, Preparo de rufião bovino por desvio lateral do prepúcio em 90º com a linha mediana ventral do abdome. *Ciência Animal Brasileira*, 5:93-97

Nomina Anatomica Veterinária, 1983, *International commitee on veterinary gross anatomical nomenclature*, Ithaca, 3 ed, p. 209

Rabelo, ER, Alves, JF, Lima, CRO, 2009, Remoção parcial do ligamento apical do pênis como alternativa cirúrgica no preparo de rufiões bovinos. In: XXXVI Congresso Brasileiro de Medicina Veterinária, Porto Seguro. *Anais...* Porto Seguro, CONBRAVET

Rabelo, ER, Silva, LAF, Brito, LAB, et al, 2008, Desmotomia apical experimental em bovinos e efeitos na indução do desvio peniano. *Veterinaria e Zootecnia* 15:312-324

Raiser, AG, 1995, Patologia Cirúrgica Veterinária, Santa Maria: Universidade Federal de Santa Maria 1:124

Rumph, PF, Garret, PD, 1992, The ligaments of the penis of the goat and sheep. *Anatomia, Histologi, Embryologia, Journal Infomation* 21:40-47

Silva, LAF, Eurides, D, Bento, LRT, 2004, *Implante de retalho peniano homólogo na correção cirúrgica de desvio traumático de pênis em bovinos*. In: XXXI CONBRAVET – XXXI Congresso Brasileiro de Medicina Veterinária, São Luís do Maranhão. *Anais: São Luís do Maranhão*. CD-ROM

Silva, LAF, Veríssimo, ACC, Ferreira MR, et al, 2002, Papilomatose cutânea bovina: revisão de literatura. *A Hora Veterinária*, 22:27-31



Silva, LAF, Viana Filho, PRL, Alameida CF, et al, 2001, Complicações pós-operórias em bovinos submetidos a duas técnicas de orquiectomia. In: Congresso de Buiatria, 5, Campo Grande. *Anais...*, Campo Grande: Sociedade Brasileira de Buiatria, 140

Tranquili, WJ, Turmon, JC, Grimm, KA (Eds). Lumb and Jones', 2007, In: *Veterinary Anesthesia and Analgesia* (4th eds.), Blackwell Publishing, p.1996

Walker, DF, 1980, Penile surgery in the bovine: part. III. *Modern Veterinary Practice* 61:69-71

Walker DF, Vaughan JJ, 1980, *Bovine and equine urogenital surgery*. Philadelphia: Lea & Febiger, 276

